

Clinical White Paper

# Smart B-line

**mindray**

healthcare within reach



## Background

The lungs are gas containing organs and the gas medium completely reflects ultrasound, which limits the use of ultrasound in lung disease diagnosis. In 1992, Professor Daniel A. Lichtenstein, regarded as the father of lung ultrasound, published a monograph on lung ultrasound. Since then, lung ultrasound has been gradually recognized by more experts on clinical medicine and ultrasound imaging and been applied to the diagnosis and treatment of critically ill patients. A series of research has been carried out on how to treat critically ill patients with lung ultrasound [1-4]. The basic principle of lung ultrasound is as follows. The gas-fluid proportion in alveoli and interstitial changes under pathological conditions, resulting in special ultrasound signs. Different ultrasound signs correspond to different pulmonary ventilation or pathological states. In critical care medicine, bedside chest X-ray has low sensitivity, and chest CT requires transfer of critically ill patients. Both X-ray and CT are radioactive, so it is impossible to monitor the change of the patient condition in real time. Lung ultrasound is a non-radioactive, convenient, inexpensive, real-time, and easy-to-use imaging examination method. It supplements X-ray and CT examinations and plays an important role in evaluating and monitoring the diagnosis and treatment of critically ill patients. Proof from evidence-based medicine shows that ultrasound has better sensitivity and specificity than X-ray in the diagnosis of hidden pneumothorax and pleural effusion. Lung ultrasound provides real-time and dynamic performance to deepen the understanding of pulmonary pathophysiological changes [5]. Lung ultrasound has been gradually improved and standardized, became an important part of ultrasonography in diagnosing and treating critically ill patients, and plays an important role in diagnosis, treatment, and condition change evaluation. Some experts recommend that critically ill patients with mechanical ventilation be routinely examined by lung ultrasound [4].

Low-frequency probes, such as convex arrays and phased arrays, are often used in lung ultrasound. High-frequency linear arrays can also be used by lung ultrasound, mainly for pleura line analysis of the superficial chest wall to diagnose and treat diseases such as pneumothorax and pleuropathy. In most cases, lung ultrasound is performed in the supine position. The ultrasound plane can be vertical to the longitudinal plane of the intercostal space or parallel to the intercostal space during scanning.

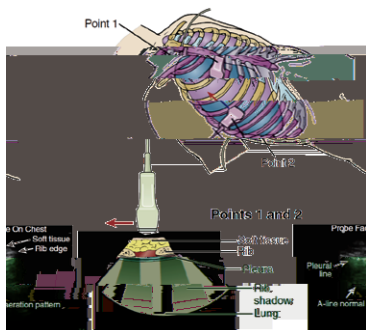


Figure 1. Lung ultrasound imaging technique and anatomic sketch

## Clinical Values

### Lung ultrasound signs

As the gas-fluid proportion in the lung decreases, the lungs gradually change from normal gasified pulmonary tissue to mild interstitial edema, severe interstitial edema, and even alveolar edema, or change from the focal to the diffuse pattern and finally to consolidation, with pleural effusion and gas in the chest. Lung ultrasound shows A-line with normal pleura sliding sign, B-line, "hepatized" lung tissue, anechoic dark area, or lung point sign in sequence [5].

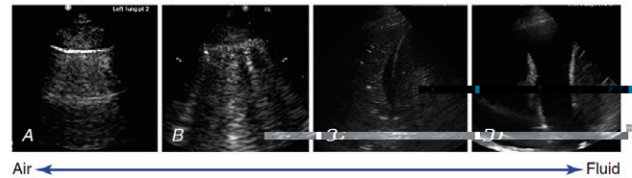


Figure 2. Relationship between the gas-fluid proportion in the lungs and lung ultrasound signs: A - A-line, normal; B - B-line, fluid in lung interstitial or alveoli; C - lung consolidation; D - pleural effusion

### B-line signs

B-line is a sign that often requires quantitative evaluation. B-line is the artifact formed by the reflection of ultrasound waves on the gas-fluid interface of alveoli. The existence of micro fluid makes partial ultrasonic waves propagate under the pleura, forming a ringing effect on the gas-fluid interface. A typical feature of the B-line is the comet tail, a narrow high echo beam from the pleura line, which does not fade with depth.



Figure 3. Feature of the B-line

The number and distribution of B-lines are determined by the degree of pulmonary ventilation dysfunction. When at least three B-lines with a distance of about 7 mm exist between two ribs in the longitudinal scan of the probe, the B-lines are caused by interlobular septal thickening, which indicates interstitial pulmonary edema. When at least three B-lines with a distance of about 3 mm or less exist between two ribs, the B-lines are caused by pulmonary alveolar edema, which is consistent with ground-glass areas observed by CT [6].




Figure 4. At least three B-lines with a distance of about 7 mm and related CT image




Figure 5. At least three B-lines with a distance of about 3 mm and related CT image

The number of B-lines can also be directly used to evaluate the amount of extravascular lung water. When lung water is of a large amount, a large area of overlapping B-lines is formed and the number of B-lines is difficult to identify. The following analysis method is proposed to facilitate quantitative analysis in clinical research: Calculate the ratio of the B-line area to the whole intercostal area and quantitatively analyze B-lines based on the area ratio [6].

## Lung ultrasound score

Bedside lung ultrasound is recommended for diagnosis to standardize the application of lung ultrasound in patients with acute respiratory failure. Bedside lung ultrasound in emergency (BLUE) and lung ultrasound score (LUS) are widely used.

LUS is performed by zone. The zoning method varies depending on different studies, and common zoning methods include 6-zone, 8-zone, and 12-zone. Many LUS methods have been proposed, and a common method is as follows. The A-line or no more than two B-lines with an obvious distance are normal lung ultrasound signs, given a score of 0 or named N. Three or more B-lines with an obvious distance indicate moderate loss of lung aeration, given a score of 1 or named B1. A large area of coalescent B-lines indicates severe loss of lung aeration, given a score of 2 or named B2. Tissue-like signs or air bronchogram signs indicate lung consolidation, given a score of 3 or named C [7].

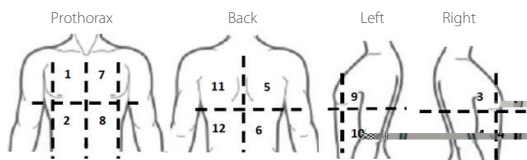


Figure 6. Schematic diagram of 12-zone lung ultrasound

LUS provides doctors with a fast and convenient semi-quantitative evaluation tool for the diagnosis of acute lung injury or

ARDS and the prognosis evaluation. Dynamic LUS monitoring can directly and effectively guide ventilator parameter tuning and ventilator withdrawal, assists with non-invasive quantitative evaluation of extravascular lung water, and locate the end point of fluid resuscitation.

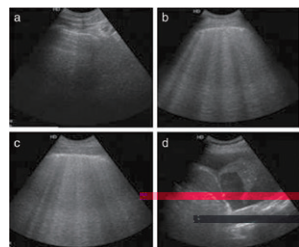


Figure 7. Four ultrasound signs in different ventilation statuses, with LUS scores of N, B1, B2, and C, respectively

## Technical Introduction

LUS has clinical limitations and most signs of lung ultrasound are artifact prone to subjective evaluation. The B-line quantification standard varies depending on different operators, which limits the standardization of clinical ultrasound. Lung ultrasound requires doctors to scan zones one by one and record results before evaluating the status. Dynamic monitoring is inefficient because it requires a more complex procedure of scanning and recording.

Smart B-line combines the machine learning algorithm and image feature extraction to automatically monitor B-lines with high repeatability and more diagnosis information, free of doctors' subjective experience. Smart B-line supports real-time and non-real-time monitoring and provides complete lung ultrasound workflow interactions to help you efficiently annotate the monitored zones and ultrasound signs.


## Quantitative Parameters

- To ensure accurate measurement, Smart B-line detects the pleura line and automatically quantifies and analyzes B-lines based on the unique texture features of lung ultrasound images. The output parameters include:
  - Rib acoustic shadow detecting: automatically detects and marks the rib acoustic shadow with yellow dotted lines, that is, the edge of ROI.
  - B-line count (B Lines): coalescent B-lines are determined when the B-line width exceeds the specified threshold. The coalescent B-lines are connected by a white line at the bottom.
  - B-line distance (Dist): automatically checks the position of the pleura line and measures the distance between two adjacent B-lines.
  - B-line area ratio (Percent): indicates the ratio of the total B-line width to the ROI width.
  - Scoring method (Score): A score of 0 (N) is given when 0 to 2 B-lines are detected. A score of 1 (B1) is given when 3 or more B-lines are detected. A score of 2 (B2) is given when coalescent B-lines are detected and the area ratio exceeds the specified threshold. A score of 3 (C) is given when you select tissue-like signs or air bronchogram signs in the fast annotation area.
  - Smart B-line supports real-time and non-real-time detecting and provides complete lung ultrasound workflow interactions to help you efficiently annotate the monitored zones and ultrasound signs.



Interactive UI Design

## Procedure



## Conclusion



## Reference Documents



Figure 11. Scoring map

Figure 12. Review in full image mode  
(only ME supported)

[www.mindray.com](http://www.mindray.com)

P/N: ENG-S a. B- i eWhi ePa e -210285X4P-20200410  
©2020 She he Mi d a Bi -Medica Eec ic C .,L.d.A igh e e ed.

**mindray**  
healthcare within reach